

## BRIEF REPORT

# Progressive Multifocal Leukoencephalopathy Complicating Treatment with Natalizumab and Interferon Beta-1a for Multiple Sclerosis

B.K. Kleinschmidt-DeMasters, M.D., and Kenneth L. Tyler, M.D.

## SUMMARY

A 46-year-old woman with relapsing–remitting multiple sclerosis died from progressive multifocal leukoencephalopathy (PML) after having received 37 doses of natalizumab (300 mg every four weeks) as part of a clinical trial of natalizumab and interferon beta-1a. PML was diagnosed on the basis of the finding of JC viral DNA in cerebrospinal fluid on polymerase-chain-reaction assay and was confirmed at autopsy. Nearly every tissue section from bilateral cerebral hemispheres contained either macroscopic or microscopic PML lesions. There was extensive tissue destruction and cavitation in the left frontoparietal area, large numbers of bizarre astrocytes, and inclusion-bearing oligodendrocytes, which were positive for JC virus DNA on in situ hybridization.

**P**ROGRESSIVE MULTIFOCAL LEUKOENCEPHALOPATHY (PML), A DEMYELINATING disease of the central nervous system (CNS), is associated with high rates of morbidity and mortality and occurs almost exclusively in immunocompromised patients.<sup>1</sup> We describe a patient with multiple sclerosis who died of PML after receiving natalizumab (Tysabri, Biogen Idec) as part of a clinical trial conducted to test the safety and efficacy of natalizumab in combination with interferon beta-1a (Avonex, Biogen Idec) in the treatment of relapsing–remitting multiple sclerosis. To our knowledge, there have been no prior reports of the concomitant association of multiple sclerosis and PML.

Natalizumab is a humanized monoclonal antibody against  $\alpha_4$  integrins that was recently introduced for the treatment of multiple sclerosis. The drug was withdrawn from the market after reports of the development of PML in two patients with multiple sclerosis who were receiving natalizumab and interferon beta-1a in clinical trials. An additional case of PML, in a patient receiving natalizumab for the treatment of Crohn's disease, is described elsewhere in this issue of the *Journal*.<sup>2</sup>

## CASE REPORT

A 41-year-old, right-handed woman began to have numbness and burning pain in her right foot and leg and tingling numbness and clumsiness in her right hand in June 1999. She had a history of migraine and transient numbness of the left hand. A neurologic examination revealed increased tone on her right side and generalized hyperreflexia (3+) with normal plantar responses. In September 1999, magnetic resonance imaging (MRI) with contrast medium showed four small, nonenhancing foci of increased signal in the

From the Departments of Pathology (B.K.K.-D.), Neurology (B.K.K.-D., K.L.T.), Neurosurgery (B.K.K.-D.), Medicine (K.L.T.), Microbiology (K.L.T.), and Immunology (K.L.T.), University of Colorado Health Sciences Center; and the Denver Veterans Affairs Medical Center (K.L.T.) — both in Denver. Address reprint requests to Dr. Kleinschmidt-DeMasters at the Department of Pathology, B-216, University of Colorado Health Sciences Center, 4200 E. 9th Ave., Denver, CO 80262.

This article was published at [www.nejm.org](http://www.nejm.org) on June 9, 2005.

N Engl J Med 2005;353:369-74.

Copyright © 2005 Massachusetts Medical Society.

corona radiata bilaterally on the fluid-attenuated inversion recovery (FLAIR) sequences. Electromyography and nerve-conduction studies showed no abnormalities. Six weeks later, her leg symptoms had improved, but the patient reported new visual blurring in her right eye. The visual acuity of the right eye was 20/100, and that of the left was 20/15. Examination of cerebrospinal fluid in November 1999 showed 1 white cell per cubic millimeter, 55 mg of protein per deciliter, and normal values for glucose (64 mg per deciliter [3.6 mmol per liter]), IgG (3.2 mg per deciliter), the IgG index (0.57), and the IgG-synthesis rate (0.3 mg per 24 hours). No oligoclonal bands were detected in a specimen of cerebrospinal fluid that was concentrated by a factor of 80. Levels of vitamin B<sub>12</sub> and folate were normal, tests for antinuclear antibodies and anticentromere antibodies were negative, and thyroid-function tests were normal. A complete blood count was also normal, except for mild leukocytosis (11,200 cells per cubic millimeter).

In January 2000, MRI showed two new nonenhancing parietal lesions with increased FLAIR signal and decreased T<sub>1</sub>-weighted signal. In February 2000, the patient reported that her vision was normal and that her right-sided numbness had nearly resolved. She began receiving 30 µg of interferon beta-1a intramuscularly each week, tizanidine, calcium, magnesium, and vitamins B, C, and E for presumed multiple sclerosis (Table 1). In May 2000, she began taking tamsulosin for difficulty with bladder emptying and citalopram for depression.

In March 2001, the patient noted worsening vision, band-like paresthesias around her back and abdomen, and increasing weakness and spasticity of her legs. The strength of both legs was mildly decreased (4+/5), and her gait was slightly spastic, although her deep tendon reflexes were normal. She received 500 mg of methylprednisolone twice daily intravenously for five days (March 16 through 20,

2001) for a suspected exacerbation of multiple sclerosis. In September 2001, she reported some decline in fine motor skills in her hands and worsening spasticity in her legs as well as some decline in cognition, including short-term memory, and began taking donepezil. She had a score of 2.5 on the Kurtzke Expanded Disability Status Scale (EDSS) in March 2002 (range of scores, 0 to 10, with higher scores indicating a greater degree of disability).

In April 2002, the patient was enrolled in a randomized, placebo-controlled, parallel-group, multicenter study designed to determine the safety and efficacy of natalizumab combined with interferon beta-1a in patients with relapsing–remitting multiple sclerosis (the Biogen Idec and Elan 1802 SENTINEL trial). At the time of her enrollment, T<sub>2</sub>-weighted MRI showed approximately nine lesions and her EDSS score was 0. She continued to take 30 µg of interferon beta-1a intramuscularly weekly throughout the study. Additional medications at study entry included citalopram, rofecoxib, and tramadol in combination with acetaminophen.

During the study, the patient received a total of 30 doses of natalizumab (300 mg, or approximately 6 mg per kilogram of body weight, each) by intravenous infusion at four-week intervals between April 12, 2002, and July 9, 2004. She also received tizanidine, donepezil, and briefly, galantamine. In July 2004, she was enrolled in an open-label extension study (Biogen Idec/Elan 1808) and received seven additional 300-mg doses of natalizumab at four-week intervals, with the last dose given on January 18, 2005. No antibodies developed against either interferon beta-1a or natalizumab. Pharmacokinetic studies showed that the clearance of natalizumab in the patient (0.0136 liter per hour) was similar to the median value in the study population (0.0138 liter per hour). A follow-up T<sub>2</sub>-weighted MRI study in April 2003 showed five new or enlarging lesions. A similar study in April 2004 showed one new or enlarging lesion. No enhancing lesions were noted. Unfortunately, these MRI scans were not available for review, and the reports specified only the number of lesions, not the location. No clinical or suspected relapses of multiple sclerosis were identified, and the patient's EDSS score remained between 0 and 2 through July 2004.

In November 2004, the patient reported new problems with hand–eye coordination, including difficulty writing and typing, as well as problems with her speech. A mental-status examination performed at that time showed a decreased fund of in-

**Table 1. Doses and Timing of Treatments for Multiple Sclerosis.**

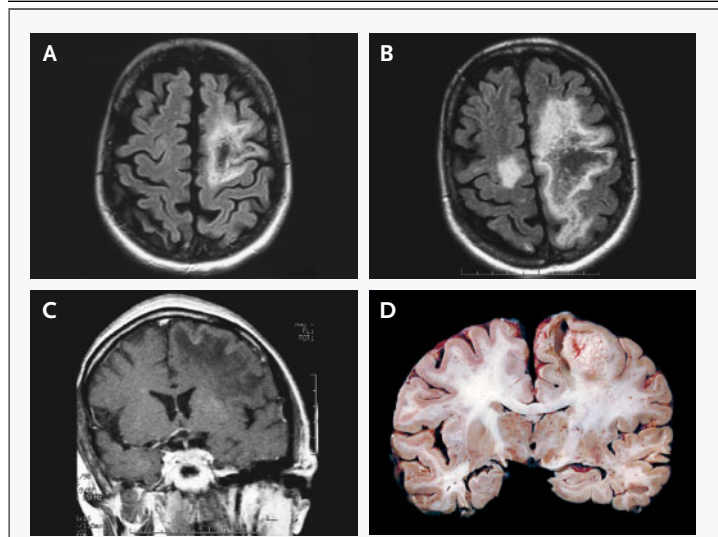
Treatment*	Treatment Interval
Interferon beta-1a, 30 µg IM	February 2000–January 2005
Methylprednisolone, 500 mg IV twice daily	March 16–20, 2001 December 15–19, 2004 January 5–9, 2005
Natalizumab, 300 mg IV every 4 weeks	April 12, 2002–January 18, 2005

\* IM denotes intramuscularly, and IV intravenously.

formation, minor errors on a drawing of a three-dimensional cube and on tests of mathematical skills, and reduced immediate recall on a word-learning test. Her cranial nerves were normal. Her strength was intact, but she had mildly increased tone in her legs and hyperactive (3+) reflexes bilaterally. In December 2004, right-sided numbness developed and word-finding difficulty increased. The patient had difficulty carrying on a conversation and became increasingly forgetful. A neurologic examination revealed difficulty with expressive speech, with preserved comprehension, some right-left confusion, irregular saccadic eye movements, and increased tone on her right side. She received methylprednisolone (500 mg intravenously twice daily) from December 15 through 19, 2004. An MRI study performed on December 15 showed a large area of increased T<sub>2</sub>-weighted and decreased T<sub>1</sub>-weighted signal in the left frontal lobe posteriorly involving the subcortical white matter and extending into the centrum semiovale and corona radiata, without enhancement or mass effect (Fig. 1A). A second area of abnormal signal was noted in the right posterior parietal lobe. On December 29, 2004, a right-sided hemiparesis with an extensor plantar response was noted.

On January 5, 2005, the patient's condition was judged to be worse, with increasing right-sided hemiparesis and worsening nonfluent aphasia. Her right-arm strength was 0/5, and her right-leg strength was 2/5 proximally and 0/5 distally. On the assumption that her clinical deterioration represented an exacerbation of multiple sclerosis, she received another five-day course of methylprednisolone, beginning on January 5, 2005 (500 mg intravenously twice daily). Her last dose of natalizumab was given on January 18, 2005. On January 24, 2005, her white-cell count was 14,400 per cubic millimeter (77 percent neutrophils, 18 percent lymphocytes, 4 percent monocytes, and 1 percent eosinophils), with an absolute lymphocyte count of 2500 per cubic millimeter.

The patient's neurologic status continued to decline, and she was hospitalized on February 12, 2005. On admission, she was unresponsive, with a right-sided gaze preference. She had a marked spastic right-sided hemiplegia and some left-sided weakness. An MRI scan obtained on February 12 (Fig. 1B and 1C) showed a dramatic increase in the extent of the high T<sub>2</sub>-weighted and low T<sub>1</sub>-weighted signal abnormalities in the left hemisphere, with extension of the lesion to the frontal, parietal, and temporal



**Figure 1. MRI Findings (Panels A, B, and C) and Autopsy Findings (Panel D).**

In Panel A, a fast spin-echo inversion recovery sequence (repetition time, 9000 msec; echo time, 91 msec; inversion time, 2500 msec) from MRI performed on December 15, 2004, shows a large PML lesion in the left frontal lobe. In Panel B, a fast spin-echo inversion recovery sequence (repetition time, 10,002 msec; echo time, 145 msec; inversion time, 2200 msec) from MRI performed on February 12, 2005, shows an increase in the size of the previously noted lesion as well as new PML lesions in the parietal and occipital lobes in the opposite hemisphere. In Panel C, a fast spin-echo sequence (repetition time, 516 msec; echo time, 10.9 msec) from MRI performed on February 12, 2005, shows a large, low-signal PML lesion underlying the cortex in the left frontoparietal white matter. For comparison with Panel C, in Panel D, a formalin-fixed coronal section of the brain shows massive coalescent areas of cavitation of the left frontoparietal white matter, leaving only a ribbon-like strip of intact overlying cortex.

lobes and across the corpus callosum to the right frontal lobe. New midbrain and pontine lesions were also present. There was no enhancement or mass effect. At admission, the patient had a white-cell count of 14,000 per cubic millimeter (77 percent neutrophils, 16 percent lymphocytes, 6 percent monocytes, and 1 percent eosinophils and basophils). Her absolute lymphocyte count was normal (2300 cells per cubic millimeter).

An examination of cerebrospinal fluid on February 14, 2005, revealed the following values: 53 mg of protein per deciliter, 90 mg of glucose per deciliter (5.0 mmol per liter), 4.3 mg of IgG per deciliter, an IgG index of 0.49, a ratio of IgG to albumin of 0.08, and an IgG-synthesis rate of 1.78 mg per 24 hours. No oligoclonal bands were noted. The results of Gram's staining of a cerebrospinal fluid sample were unremarkable. A polymerase-chain-reaction (PCR) assay of cerebrospinal fluid for herpes sim-

plex virus was negative, as were tests for West Nile virus IgG and IgM, eastern equine encephalomyelitis virus IgG and IgM, *Borrelia burgdorferi* IgG and IgM, and cryptococcal antigen and stains and cultures for bacteria, fungi, and acid-fast bacilli. A test for serum antibody against human immunodeficiency virus (HIV) type 1 and 2 was nonreactive. CD4+ and CD8+ T-cell counts were not assessed, but at no time was either absolute or relative lymphopenia noted.

The treating neurologist suspected PML, and a cerebrospinal fluid sample sent to the Mayo Medical Laboratories (Rochester, Minn.) for JC virus PCR testing was positive. The patient died on February 24, 2005; she was 46 years old.

---

#### METHODS AND RESULTS

---

Postmortem examination showed bilateral aspiration pneumonia and cachexia. There was prominent sinus histiocytosis of the lymph nodes and possible depletion of CD8+ T cells in comparison with the levels of CD4+ T cells, probably owing to severe terminal debilitation. Examination of the bone marrow showed a clinically significant leftward shift in granulocytic maturation. All other systemic organs were histologically normal; no non-CNS opportunistic infections were found. Postmortem blood samples were not tested for JC virus DNA or antibody.

The formalin-fixed, 1140-g brain was fluctuant on palpation over a large portion of the anterior left hemisphere; no discoloration or meningeal opacification was present. On coronal sectioning, this softened area corresponded to massive, coalescent areas of severe cavitation involving most of the left frontoparietal white matter, leaving only a ribbon-like strip of intact overlying cortex (Fig. 1D). Smaller, noncavitated, ovoid areas of discoloration, a typical feature of PML, studded the remaining left-hemispheric white matter, particularly at the junctions between cortical gray matter and white matter, and involved the right superior frontal gyrus (Fig. 2A). A 7-mm lesion was identified in the left cerebral peduncle (Fig. 2B and 2C). No multiple-sclerosis plaques were discernible in the corona radiata.

The brain stem, spinal cord, and optic chiasm were submitted in toto for histologic examination. Sections (total, 73 blocks) from the brain and spinal cord were stained with hematoxylin and eosin, with one fourth of the sections also stained with Luxol fast blue and periodic acid-Schiff for myelin. All sections were devoid of acute anoxic injury and vascu-

litis. Areas of PML showed near-total loss of myelin, an influx of macrophages, and numerous reactive astrocytes, but no perivascular or parenchymal lymphocytic inflammation (Fig. 2D). Astrocytes with bizarre, enlarged hyperchromatic nuclei, a typical finding in PML, were common, even in smaller lesions (Fig. 2D). There were large numbers of oligodendrocytes with the classic violaceous intranuclear inclusions of PML (Fig. 2E). Cells with inclusions had a strong positive signal for JC virus DNA on in situ hybridization (probe 40847, Enzo Life Sciences) (Fig. 2F).

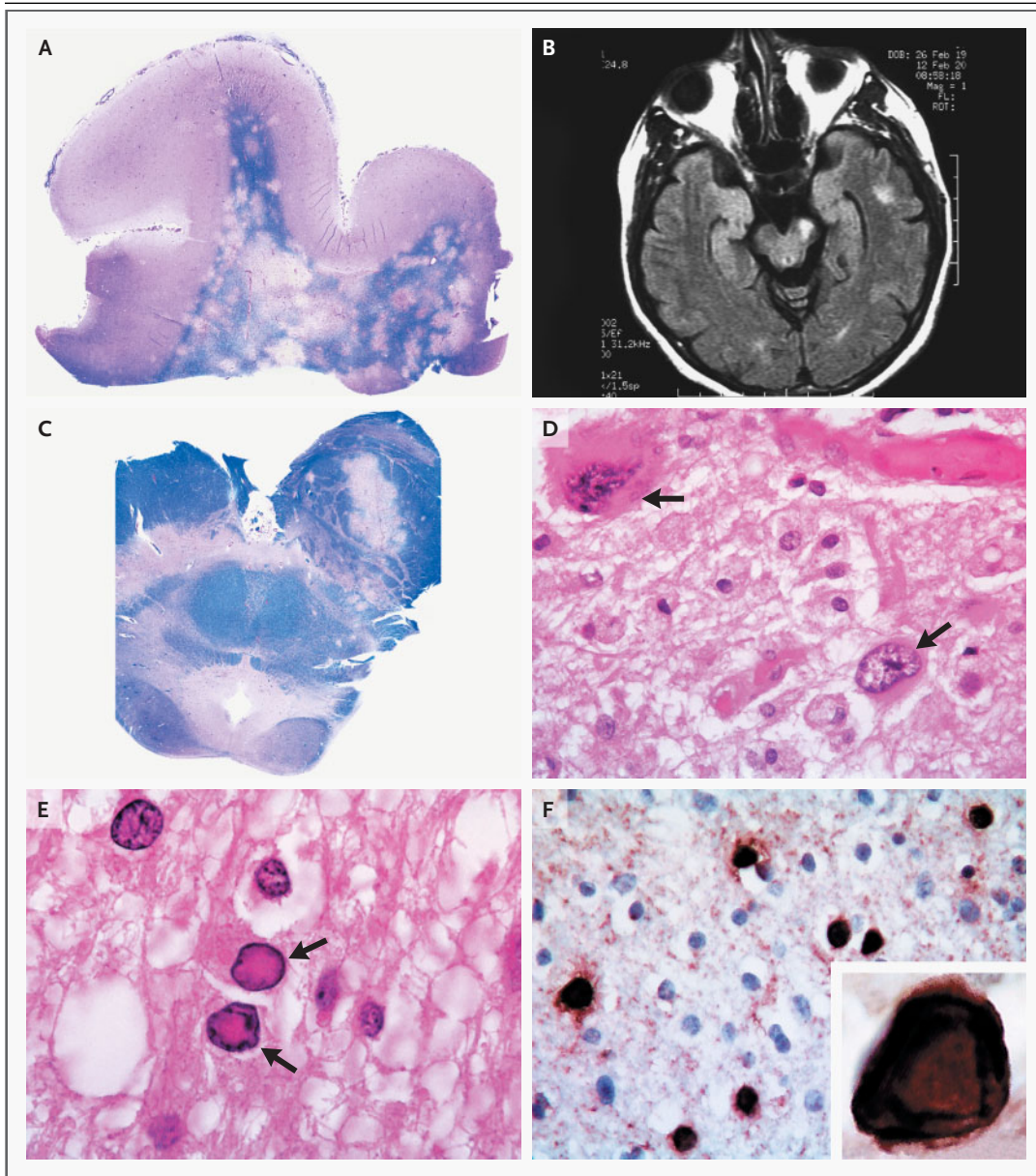
In addition to the PML lesions seen on gross examination, myriad minute lesions were easily identified microscopically in virtually every section examined from the left cerebral hemisphere, as well as in most of the sections from the right side and all of the brain-stem sections. PML was found only focally in the cerebellum; no granule-cell depletion was seen. The optic nerve, chiasm, and spinal cord contained neither PML lesions nor multiple-sclerosis demyelinating lesions. Examination of the spinal cord showed unilateral wallerian degeneration that was due to the cavitated lesions involving the left motor strip and internal capsule. Remote cortical microinfarctions were found in the right superior frontal and parietal gyri and splenium of the corpus callosum.

---

#### DISCUSSION

---

PML is a demyelinating disease of the CNS caused by lytic infection of oligodendrocytes by JC polyomavirus. Primary JC virus infection occurs in childhood and is asymptomatic. JC virus antibodies are detectable in approximately 50 to 70 percent of the adult population.<sup>3,4</sup> After the primary infection, JC virus remains latent in kidneys and lymphoid organs. Up to 64 percent of healthy adults have shedding of JC virus in urine in the absence of any clinical symptoms, suggesting that asymptomatic active JC virus infection is common in immunocompetent persons.<sup>5</sup> In contrast, PML occurs almost exclusively in immunocompromised persons, particularly those with depressed cell-mediated immunity resulting from HIV infection, hematologic cancers, or immunosuppressive medications.<sup>1</sup> In recipients of bone marrow transplants, PML has also been associated with treatment with rituximab, an antibody against CD20 expressed on B cells,<sup>6</sup> and cases of PML-like CNS demyelinating illness have been reported in patients with rheumatic diseases treated



**Figure 2. Histologic and MRI Findings.**

Panel A shows smaller, noncavitated, ovoid areas of discoloration typical of PML studding the left-hemispheric white matter, particularly at the junctions of cortical gray matter and white matter, as well as the right superior frontal gyrus (whole-mount section stained for myelin with Luxol fast blue–periodic acid–Schiff). In Panel B, a fast spin–echo inversion recovery sequence (repetition time, 10,002 msec; echo time, 145 msec; and inversion time, 2200 msec) from MRI performed on February 12, 2005, shows PML lesions in the left cerebral peduncle of the midbrain, left temporal lobe, and both occipital lobes. For comparison with Panel B, Panel C shows a discrete PML lesion, 7 mm in diameter, in the left cerebral peduncle (whole-mount section stained for myelin with Luxol fast blue and periodic acid–Schiff). In Panel D, PML lesions are characterized by a near-total loss of myelin, an influx of macrophages, and numerous bizarre astrocytes (arrows), but no perivascular or parenchymal lymphocytic inflammation (hematoxylin and eosin). Panel E shows large numbers of oligodendrocytes with the violaceous intranuclear inclusions characteristic of PML; several infected glial cells are also present (arrows) (hematoxylin and eosin). In Panel F and the inset, cells with inclusions have a strong positive nuclear signal for JC virus (dark reddish brown) of PML on in situ hybridization (diaminobenzidine used as the chromagen with a light hematoxylin counterstain).

with antagonists of tumor necrosis factor  $\alpha$ .<sup>7</sup> Although multiple sclerosis is an immune-mediated disorder, to our knowledge, patients with multiple sclerosis have not previously been identified as at increased risk for PML.

Natalizumab is a humanized monoclonal antibody against  $\alpha_4$  integrins that was approved by the Food and Drug Administration for the treatment of several immune-mediated disorders, including multiple sclerosis and inflammatory bowel disease.<sup>8-10</sup> Antibodies against  $\alpha_4$  integrins inhibit the binding of cells expressing  $\alpha_4\beta_1$  integrin and  $\alpha_4\beta_7$  integrin (e.g., lymphocytes) to vascular-cell adhesion molecule 1 and mucosal addressin-cell adhesion molecule 1 on endothelial cells, a critical step in the diapedesis of lymphocytes across blood vessels into the CNS and mucosal organs.<sup>10,11</sup> Treatment with antibodies against  $\alpha_4$  integrins prevents inflammatory cells from crossing the blood-brain barrier and inhibits the accumulation of immune cells in the CNS in animals with experimental allergic encephalomyelitis.<sup>11-13</sup>

Our patient received interferon beta-1a for nearly five years and received combined therapy with natalizumab and interferon beta-1a for just over two years as part of the SENTINEL trial. We therefore cannot rule out a potential contributory role of interferon beta-1a in the genesis of this patient's PML.

However, to date, there have been no reported cases of PML in patients receiving interferon beta-1a monotherapy.

The diagnosis of PML was established on the basis of a positive PCR assay for JC viral DNA in cerebrospinal fluid in a patient with clinical and neuroimaging findings that were typical of PML, and the diagnosis was confirmed at autopsy. The severity and extent of disease were dramatic. Nearly every tissue section from bilateral cerebral hemispheres that we examined had either macroscopic or microscopic PML lesions, ranging from minute to massive in size. There was extensive tissue destruction and cavitation in the left frontoparietal area, and the lesions contained large numbers of oligodendrocytes with inclusions. No inflammatory response was present. Although no formal quantitation was performed, the extent of the PML involvement was similar to or exceeded that seen in HIV-infected patients before the advent of highly active antiretroviral therapy.

Dr. Tyler is supported by the Reuler-Lewin Family Professorship of Neurology.

We are indebted to the neurologist who cared for the patient; to Dr. Kate Dawson from Biogen Idec, for furnishing some additional clinical and laboratory information on the patient; to Ms. Lisa Litzenberger for her photographic expertise; to the histologic technicians, supervised by Mr. David Davis, for slide preparation; and to Ms. Cindy McNair for assistance in the preparation of the manuscript.

#### REFERENCES

1. Koralnik IJ. New insights into progressive multifocal leukoencephalopathy. *Curr Opin Neurol* 2004;17:365-70.
2. Van Assche G, Van Ranst M, Sciot R, et al. Progressive multifocal leukoencephalopathy after natalizumab therapy for Crohn's disease. *N Engl J Med* 2005;353:362-8.
3. Knowles WA, Pipkin P, Andrews N, et al. Population-based study of antibody to the human polyomaviruses BKV and JCV and the simian polyomavirus SV40. *J Med Virol* 2003;71:115-23.
4. Stolt A, Sasnauskas K, Koskela P, Lehtinen M, Dillner J. Seroepidemiology of the human polyomaviruses. *J Gen Virol* 2003;84:1499-504.
5. Gasnault J, Kahraman M, de Goer de Herve MG, Durali D, Delfraissy JF, Taoufik Y. Critical role of JC virus-specific CD4 T-cell responses in preventing progressive multifocal leukoencephalopathy. *AIDS* 2003;17:1443-9.
6. Goldberg SL, Pecora AL, Alter RS, et al. Unusual viral infections (progressive multifocal leukoencephalopathy and cytomegalovirus disease) after high-dose chemotherapy with autologous blood stem cell rescue and peritransplantation rituximab. *Blood* 2002;99:1486-8.
7. Imperato AK, Bingham CO III, Abramson SB. Overview of benefit/risk of biological agents. *Clin Exp Rheumatol* 2004;22:Suppl 35:S108-S114.
8. Miller DH, Khan OA, Sheremata WA, et al. A controlled trial of natalizumab for relapsing multiple sclerosis. *N Engl J Med* 2003;348:15-23.
9. Ghosh S, Goldin E, Gordon FH, et al. Natalizumab for active Crohn's disease. *N Engl J Med* 2003;348:24-32.
10. Rice GPA, Hartung H-P, Calabresi PA. Anti-alpha4 integrin therapy for multiple sclerosis: mechanisms and rationale. *Neurology* 2005;64:1336-42.
11. von Andrian UH, Engelhardt B.  $\alpha_4$  Integrins as therapeutic targets in autoimmune disease. *N Engl J Med* 2003;348:68-72.
12. Yednock TA, Cannon C, Fritz LC, Sanchez-Madrid F, Steinman L, Karin N. Prevention of experimental autoimmune encephalomyelitis by antibodies against  $\alpha_4\beta_1$  integrin. *Nature* 1992;356:63-6.
13. Kent SJ, Karlik SJ, Cannon C, et al. A monoclonal antibody to alpha 4 integrin suppresses and reverses active experimental allergic encephalomyelitis. *J Neuroimmunol* 1995;58:1-10.

Copyright © 2005 Massachusetts Medical Society.